

## CASE REPORT

# Management of Endodontic Failure

<sup>1</sup>Meenu M Kumar, <sup>2</sup>K Radhakrishnan Nair, <sup>3</sup>Praveena Geetha, <sup>4</sup>Faisal Nazar, <sup>5</sup>Rinsu N Alexander, <sup>6</sup>Aparna Raj

## ABSTRACT

There are several reasons for a root canal therapy to be unsuccessful. One of the causes for endodontic failure is instrument separation. As a consequence of fracture, access to the apical portion of the root canal is obstructed, leading to improper disinfection. The retrieval of separated instrument followed by obturation to the working length is the treatment option. Many factors can make retrieval difficult. In such cases, management can be done even by bypassing the separated instrument. Another factor for endodontic failure is underobturation. It may be due to block or ledge in the apical third of the canal. Proper instrumentation with frequent confirmation of apical patency during instrumentation can prevent formation of ledge. The inability to treat all the canals is the other cause leading to endodontic failure. Bacteria residing in these canals lead to the persistence of symptoms. Proper evaluation of the radiograph with proper deroofting can prevent chances for missed canals. Combination of all these factors can make retreatment difficult. This case report discusses two endodontic failure cases. In the first case, a premolar tooth with separated instrument and incomplete obturation was treated by retrieval of separated instrument and the obturation of both canals to working length was done. The second one was a molar tooth which had a missed canal, a separated instrument, and an incomplete obturation. Missed canal was negotiated and the fractured instrument was bypassed and root canal was obturated.

**Keywords:** Endodontic failure, Radix entomolaris, Separated instrument, Ultrasonic.

**How to cite this article:** Kumar MM, Nair KR, Geetha P, Nazar F, Alexander RN, Raj A. Management of Endodontic Failure. *Cons Dent Endod J* 2017;2(2):60-64.

**Source of support:** Nil

**Conflict of interest:** None

## INTRODUCTION

Endodontic treatment has a reported success rates up to 86 to 98%, and there is no consistent definition for "success" criteria of endodontic treatment.<sup>1</sup> Endodontic

failure has been defined in some studies as a recurrence of clinical symptoms along with the presence of a periapical radiolucency.<sup>2</sup> An endodontically treated tooth should be evaluated clinically as well as radiographically for its root canal treatment to be deemed successful. There are several anatomic and iatrogenic factors that can lead to endodontic failure. One of the foremost causes of endodontic failure is persistent microbiological infection.<sup>3</sup> The role of bacteria in periradicular infection has been well established in the literature, and endodontic treatment will result in higher chance of failure if microorganisms persist in the canals at the time of root canal obturation.<sup>4</sup> Apart from proper disinfection and debridement of canals, another factor which is of importance is the quality of obturation. In a study which assessed teeth with endodontic failures, 65% of the cases exhibited poor quality obturation, whereas 42% of the teeth had some canals which were left untreated.<sup>5</sup> In another study, an association was found between increased incidence of periapical periodontitis and inadequate or overextended root fillings.<sup>6</sup>

A well-sealing coronal restoration is essential after the completion of obturation as it would prevent the ingress of any microorganisms, which are present in the ambient environment.<sup>7</sup> Swanson and Madison<sup>8</sup> emphasized in their study that coronal leakage should be considered as a potential factor resulting in endodontic failure. The importance of a good quality coronal restoration was also emphasized by Ray and Trope<sup>9</sup> in their study. Ng et al,<sup>10</sup> in their meta-analysis stated that pooled success rate for teeth which have satisfactory restorations is higher than those teeth which have poor quality restorations. Another factor for endodontic failure is instrument separation. As a consequence of fracture, the access to the apical portion of the root canal is decreased and this could have a deleterious effect on canal disinfection and, later on, on obturation. Most of the studies done on the effect of fractured instruments have demonstrated minimal influence on the success rate of the treatment.<sup>11</sup> The stage of instrumentation at which the instrument breaks can have an effect on the prognosis. Disinfection and obturation of the part of canal distal to the fractured instrument become difficult, possibly leading to the presence of persistent infection in that area.<sup>12</sup> However, the fractured instrument itself has less to do with failure because most of the times, success is only affected when a concomitant infection is present.<sup>13</sup>

<sup>1,4-6</sup>Postgraduate Student, <sup>2</sup>Professor and Head, <sup>3</sup>Professor

<sup>1-6</sup>Department of Conservative Dentistry and Endodontics, Azeezia College of Dental Sciences & Research, Kollam Kerala, India

**Corresponding Author:** Meenu M Kumar, Postgraduate Student Department of Conservative Dentistry and Endodontics, Azeezia College of Dental Sciences & Research, Kollam, Kerala, India Phone: +919061929995, e-mail: meenumenumk@gmail.com

It is not an uncommon practice to miss a canal while carrying out endodontic treatment especially in molar teeth where number of canals is more than the number of roots. Moreover, a less than adequate access opening makes it difficult for the primary dentist to locate the supplemental canals. The inability to treat all the canals is one of the causes leading to endodontic failure. Bacteria residing in these canals lead to the persistence of symptoms. In a prospective study carried out by Hoen and Pink,<sup>6</sup> the incidence of missed canals was reported to be 42% of all the 1,100 endodontically failed cases.

This case series is about two cases of endodontic failures that had fractured instruments, underobtured and missed root canals and its management to obtain a three-dimensional obturation.

## CASE REPORTS

### Case 1

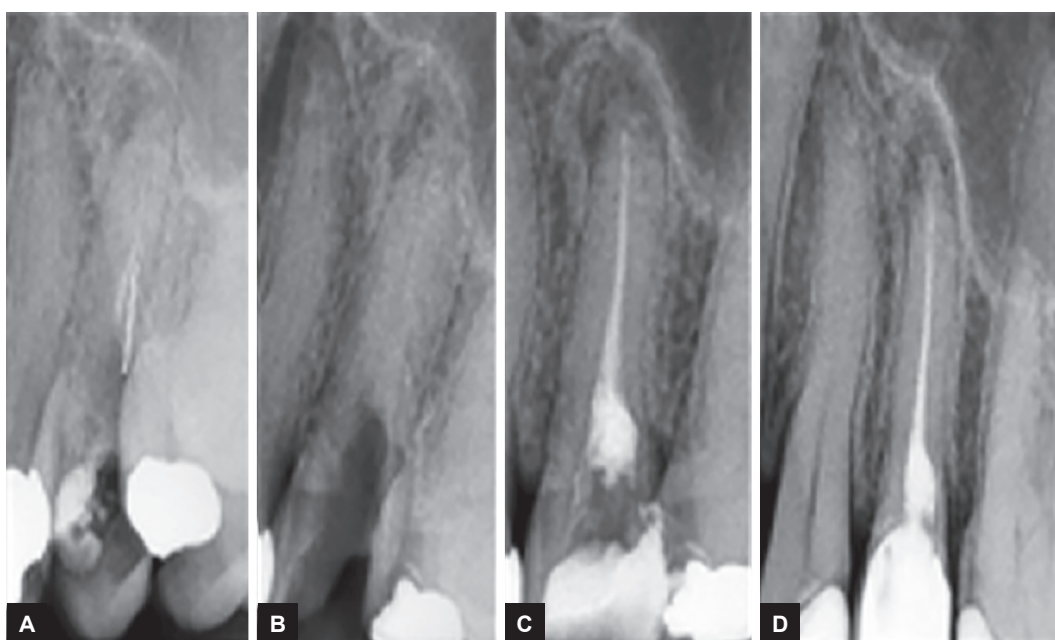A 34-year-old female patient came to the department with the complaint of dislodged restoration in relation to upper left back tooth (25) for past 2 months. She had given a history of root canal treatment in affected tooth 5 years back in another clinic and failed to place the crown. She had also given a history of pain in the affected tooth while chewing. There was no relevant medical history and had a dislodged restoration in relation to 25 with exposed gutta-percha. On percussion, tenderness was present. Radiograph of tooth in both mesial and distal angulation revealed incomplete obturation on the palatal canal. There was a broken instrument of about 4 mm length on the

cervical third of buccal canal (Fig. 1A). Periapical radiolucency was evident on the tooth. Treatment plan was to go for root canal retreatment in relation to 25.

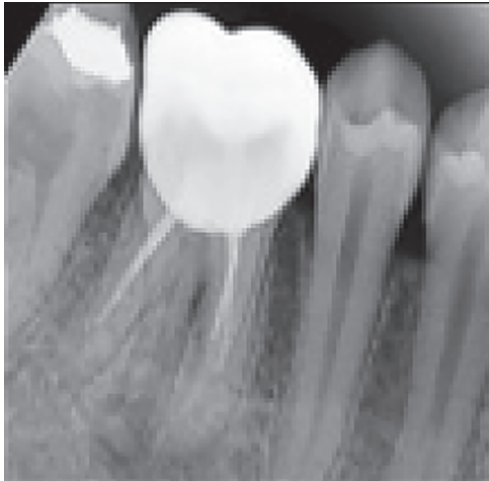
On the first appointment, under rubber dam isolation, gutta-percha was removed from the palatal canal using gutta-percha solvents (Endosolv E) and H-files (Mani, Japan) and working length determination of that canal was done. Staging platform was created on the buccal canal using modified Gates Glidden drills (size 3). Separated instrument was retrieved from the canal with the aid of magnifying loupe (2.5×) and ultrasonic tip (Woodpecker-UDS, ET-1) after blocking palatal canal orifice with cotton pellet (Fig. 1B). Cleaning and shaping of both the canals was done and obturated using lateral compaction technique (Fig. 1C). After 2 weeks, patient was reviewed and was asymptomatic. Hence, coronal seal was done with resin composite followed by crown placement. Follow up examination was done after six months. Patient was asymptomatic and radiograph showed reduction in size of periapical radiolucency.(Fig. 1D)

### Case 2

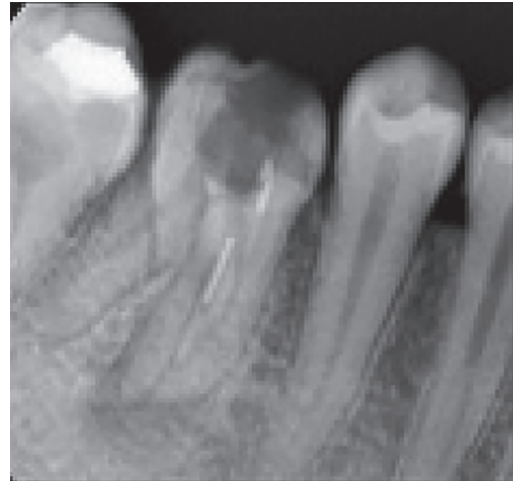A 20-year-old female patient came to the department with the complaint of pain while chewing in lower right back tooth for past 1 month. She had given a history of root canal treatment in affected tooth 3 months earlier in another clinic. There was no relevant medical history. Intraoral examination revealed metal ceramic crown in relation to 46 with tenderness on percussion. Intraoral periapical radiograph of 46 showed incomplete obturation on the mesiolingual canal and there was an instrument



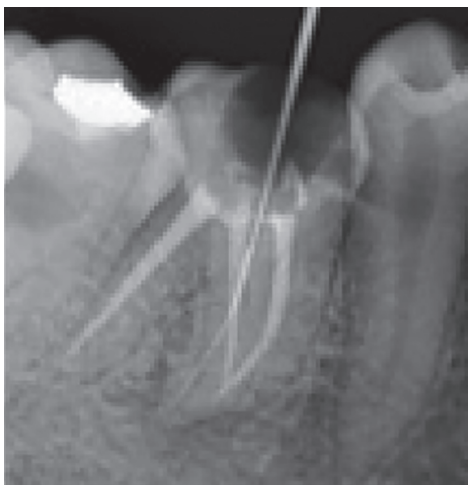**Figs 1A to D:** (A) Preoperative view; (B) after instrument retrieval using ultrasonic; (C) after obturation; and (D) recall after 6 months



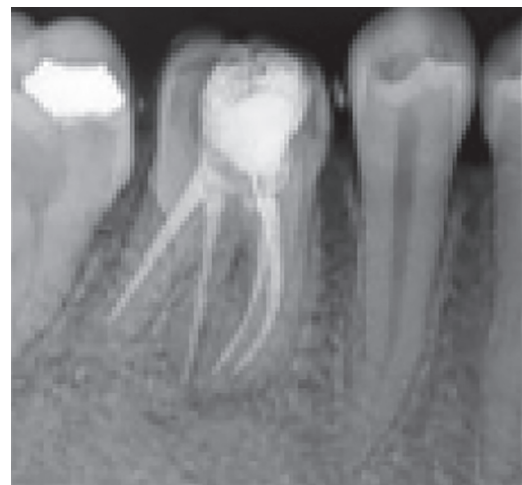**Fig. 2:** Preoperative view



**Fig. 3:** After gutta-percha removal—separated instrument in one of the mesial canals



**Fig. 4:** Obturated distobuccal, distolingual, mesiolingual canal and bypassed separated instrument in mesiobuccal canal



**Fig. 5:** Postoperative composite followed by crown placement

fracture in the mesiobuccal canal as distinguished by tube shift technique. There was an additional distolingual root. The distobuccal root was under-obturated and the distolingual root was unobturated. Radiolucency was seen at the periapical aspect of mesial root and one distal root (Fig. 2). Treatment plan was to go for root canal retreatment in relation to 46.

On the first appointment, coronal access was gained by sectioning the metal ceramic crown and removing the existing coronal amalgam restoration. Under rubber dam isolation, gutta-percha was removed from mesiolingual and distal canal using gutta-percha solvents (Endosolv E) and ProTaper retreatment files (D1, D2, D3; Dentsply, Switzerland) (Fig. 3). Missed canal of distolingual root was located (radix entomolaris) after modifying the pulp chamber. Working length of the three canals was determined. Repeated attempt was done for retrieval of separated instrument using ultrasonic and was unsuccessful. Hence, cleaning and shaping of other three canals

(mesiolingual, distobuccal, distolingual) was done on that appointment up to F2 ProTaper universal system and was obturated using ProTaper F2 gutta-percha points. Orifice of three canals was sealed with glass ionomer cement. After sealing the orifice, cotton pellet was placed on the orifice of mesiobuccal canal and temporary filling was given.

On the second appointment, attempt to retrieve the separated instrument continued and was able to manage it by bypassing using 10 size k-file and the working length was estimated (mesiobuccal 18 mm) (Fig. 4). Cleaning and shaping of the mesiobuccal canal was done and obturated using cold lateral compaction (Fig. 5). After 2 weeks, patient was reviewed and the coronal seal was done with resin composite followed by crown placement.

## DISCUSSION

Retreatment is indicated in failed endodontically treated tooth. Several factors need to be considered before going



for a retreatment, which includes evaluation of root canal anatomy, quality of obturation, and iatrogenic complications. When presented with a tooth in need of retreatment that has a full-coverage restoration, the decision for the clinician becomes whether to preserve the restoration or plan its replacement. Here, the molar crown was sectioned and removed using transmetal bur to increase the visibility and accessibility, followed by removal of existing amalgam restoration to gain access to previous root canal-filled material. In both the cases, previous root canal obturated material was gutta-percha, which was removed using gutta-percha solvents (Endo-solv E) and H-files (Mani, Japan) in premolar tooth and ProTaper retreatment files (Dentsply, Switzerland) in molar tooth.

The second case was radix entomolaris. In mandibular first molar, radix entomolaris was seen in about 5.3% cases. The orifice of radix entomolaris may be located either distolingually or mesiolingually from the distal canal. It can be located by a dark line or groove from the main canal on the pulp chamber floor leading to the orifice. Here, it was found on the mesiolingual side of main canal. Knowledge of root canal anatomy and its variations, proper evaluation of radiograph, and proper access and deroofing are important to prevent a missed canal.

Even though there are several causes for instrument separation, most important cause is the improper use of the instrument. An instrument fracture within the root canal interferes and hinders the outcome of the successful root canal treatment. In the premolar tooth, instrument fracture was about 2 mm below cemento-enamel junction and ultrasonic tip could safely be placed between canal wall and instrument and due to the vibration force the fragment was moved out of the canal. The use of ultrasonic devices for the management of separated fragments has shown successful results avoiding further canal obstructions and is advantageous over conventional methods for retrieval of separated instruments as it is able to set separated instruments free from canals without sacrificing the dentin.<sup>14</sup> The removal of the broken fragments with traditional methods is time-consuming, risky, and has limited success. This technique is simpler and less invasive. Removal of separated instruments is often advised but several factors can make retrieval difficult. As an alternative method, bypassing technique is used. In the molar tooth, separated instrument retrieval was attempted using ultrasonic and was unsuccessful but was bypassed using small size file and obturation was done with the separated instrument in the canal. A study considered 8,460 teeth and concluded that the presence of a fragment of fractured instrument in the root canal did

not significantly influence the success rate of endodontic treatment by 91.8% if fragment is present, and 94.5% if not.<sup>15</sup> During retreatment, the root canal system should be considered as contaminated and the presence of a retained instrument fragment may prevent access to the apical third of the canal, thus compromising disinfection.

There was a ledge or block on the mesiolingual and distobuccal canal of molar teeth. After several instrumentation with 6 and 8 size k-file along with proper irrigation and lubrication with RC prep, the apical third of the canal was able to be negotiated. After regaining the apical extent of the canal system, routine endodontic procedures are instituted to complete the retreatment.

## CONCLUSION

Root canal treatment fails when the treatment is carried out inadequately. As we continue to strive to maintain healthy natural teeth for our patients, endodontic retreatment should be the primary option for patients with posttreatment disease. Any obstruction hindering proper cleaning and shaping should be tried to remove completely during retreatment for better prognosis of the tooth. Here, in both cases, endodontic failure was retreated by negotiation of missed canal, regaining apical extent of underfilled canals; removal of separated instrument in premolar teeth was managed by retrieval using ultrasonic and molar teeth bypassing separated instrument and obturation was done to the working length. The patient was asymptomatic after 6 months follow-up.

## REFERENCES

1. Song M, Kim HC, Lee W, Kim E. Analysis of the cause of failure in nonsurgical endodontic treatment by microscopic inspection during endodontic microsurgery. *J Endod* 2011 Nov;37(11):1516-1519.
2. Ashley M, Harris I. The assessment of the endodontically treated tooth. *Dent Update* 2001 Jun;28(5):247-252.
3. Endo MS, Ferraz CC, Zaia AA, Almeida JF, Gomes BP. Quantitative and qualitative analysis of microorganisms in root-filled teeth with persistent infection: monitoring of the endodontic retreatment. *Eur J Dent* 2013 Jul;7(3):302-309.
4. Sjögren U, Figdor D, Persson S, Sundqvist G. Influence of infection at the time of root filling on the outcome of endodontic treatment of teeth with apical periodontitis. *Int Endod J* 1997 Sep;30(5):297-306.
5. Segura-Egea JJ, Jiménez-Pinzón A, Poyato-Ferrera M, Velasco-Ortega E, Ríos-Santos JV. Periapical status and quality of root fillings and coronal restorations in an adult Spanish population. *Int Endod J* 2004 Aug;37(8):525-530.
6. Hoen MM, Pink FE. Contemporary endodontic retreatments: an analysis based on clinical treatment findings. *J Endod* 2002 Dec;28(12):834-836.
7. Melike Bayram H, Celikten B, Bayram E, Bozkurt A. Fluid flow evaluation of coronal microleakage intraorifice barrier

- materials in endodontically treated teeth. *Eur J Dent* 2013 Jul-Sep;7(3):359-362.
8. Swanson K, Madison S. An evaluation of coronal microleakage in endodontically treated teeth. Part I. Time periods. *J Endod* 1987 Feb;13(2):56-59.
  9. Ray HA, Trope M. Periapical status of endodontically treated teeth in relation to the technical quality of the root filling and the coronal restoration. *Int Endod J* 1995 Jan;28(1):12-18.
  10. Ng YL, Mann V, Rahbaran S, Lewsey J, Gulabivala K. Outcome of primary root canal treatment: systematic review of literature—part 2. Influence of clinical factors. *Int Endod J* 2008 Jan;41(1):6-31.
  11. Simon S, Machtou P, Tomson P, Adams N, Lumley P. Influence of fractured instruments on the success rate of endodontic treatment. *Dent Update* 2008 Apr;35(3):172-174, 176, 178-179.
  12. Kerekes K, Tronstad L. Long-term results of endodontic treatment performed with a standardized technique. *J Endod* 1979 Mar;5(3):83-90.
  13. Siqueira JF Jr. Aetiology of root canal treatment failure: why well-treated teeth can fail. *Int Endod J* 2001 Jan;34(1):1-10.
  14. Madarati AA, Hunter MJ, Dummer PM. Management of intracanal separated instrument. *J Endod* 2013 May;39(5):569-581.
  15. Spili P, Parashos P, Messer HH. The impact of instrument fracture on outcome of endodontic instrument. *J Endod* 2005 Dec;31(12):845-850.