

## CASE REPORT

# Management of a Complicated Vertical Crown Fracture

<sup>1</sup>Aparna Raj, <sup>2</sup>K Radhakrishnan Nair, <sup>3</sup>Praveena Geetha, <sup>4</sup>Aadit Anilkumar, <sup>5</sup>Rinsu N Alexander, <sup>6</sup>Meenu M Kumar

## ABSTRACT

Coronal fractures of the anterior teeth are a common form of dental trauma affecting mainly children and adolescents. Trauma with accompanying fracture of anterior teeth is an agonizing experience for a young individual, which requires immediate attention, not only because of the physical disfigurement but also because of the psychological impact on the patient. Coronal fractures may be vertical or horizontal. Vertical crown fracture with pulpal involvement usually presents mild symptoms and pain. Pain is mainly due to the mobility of the fractured segment during function. This study describes the single-visit management of a complicated vertical coronal fracture in a maxillary central incisor. Esthetic management of the fracture line was done by resin composite by preparing grooves and followed by joining the fragments together. After esthetic management, endodontic treatment was done for the tooth. Crown was given at a later stage to prevent the extension of fracture line and for the longevity of tooth.

**Keywords:** Composite, Coronal fractures, Trauma.

**How to cite this article:** Raj A, Nair KR, Geetha P, Anilkumar A, Alexander RN, Kumar MM. Management of a Complicated Vertical Crown Fracture. *Cons Dent Endod J* 2017;2(2):52-55.

**Source of support:** Nil

**Conflict of interest:** None

## INTRODUCTION

Anterior teeth are more prone to fracture due to trauma and is affecting mainly children and adolescents. Crown fracture is the most common type of dental injury after trauma to permanent teeth.<sup>1</sup> Most dental injuries involve single tooth, and the majority of the affected teeth are maxillary central incisors.<sup>2</sup> This may be attributable to their anterior position and protrusion caused by the eruptive pattern.<sup>3</sup> Coronal fractures of permanent incisors represent 18 to 22% of all trauma to dental hard tissues, 28 to 44% being simple (enamel and dentin) and 11 to 15% complex (enamel, dentin and pulp).<sup>4,5</sup> Coronal

fractures may be vertical or horizontal. Vertical root fracture is the fracture involving enamel dentin and cementum exposing the pulp. Vertical fractures may be complete and incomplete based on the separation of fragments and also classified relative to the position of alveolar crest as intraosseous and supraosseous.

Vertical crown fracture with pulpal involvement usually involves pain. Pain is mainly due to the mobility of the fractured segment during function. In case of irreversible pulpal changes endodontic therapy is warranted.<sup>4,6</sup> Identifying the vertical root fractures is often an endodontic challenge. Diagnosis of vertical fractures includes history, clinical examination, radiographic examination, which reveals J-shaped lesion and halo-like bone loss. Staining, tracing the sinus, periodontal probing, and surgical exploration are also helpful in diagnosis. Clinical findings should be carefully observed and correlated with radiographic findings to obtain correct diagnosis. The introduction of cone beam computed tomography (CBCT) imaging facilitated the transition from a two-dimensional to a three-dimensional approach in image acquisition and interpretation and thus helps in the diagnosis of root fractures and other dentoalveolar trauma with high accuracy and sensitivity. Superimposition of neighboring structures is one of the limitations of conventional radiography, which further limits the ability to detect root fractures. Small change in the horizontal angulation can render the fracture undetectable in conventional radiography. So CBCT is more sensitive than conventional radiography in the detection of vertical fractures.

There are several factors that influence the management of coronal tooth fractures. They are the extent of fracture, pattern of fracture, secondary trauma injuries, presence/absence of fractured tooth fragment and its condition for use, occlusion, esthetics, finances, and prognosis.<sup>7-9</sup> A number of techniques have been developed to restore the fractured crown, which ranges from simple composite resin restoration to jacket crown with acrylic resin or porcelain. Orthodontic bands are used to stabilize the fracture fragment and also to some extent to pin-retained resin restoration and fragment reattachment. Various treatment modalities are available depending on clinical, physiological, and radiographic status of the teeth. This study describes the single-visit management of a complicated vertical coronal fracture of a maxillary central incisor.

<sup>1,4-6</sup>Postgraduate Student, <sup>2</sup>Professor and Head, <sup>3</sup>Professor

<sup>1-6</sup>Department of Conservative Dentistry and Endodontics  
Azeezia College of Dental Sciences & Research, Kollam  
Kerala, India

**Corresponding Author:** Aparna Raj, Postgraduate Student  
Department of Conservative Dentistry and Endodontics, Azeezia  
College of Dental Sciences & Research, Kollam, Kerala, India  
Phone: +919946322740, e-mail: dr.aparnadeepak@gmail.com

## CASE REPORT

A 15-year-old male patient reported to the department with complaint of pain in relation to upper front tooth. He had trauma on the previous day. There was no relevant medical history. On intraoral examination, the upper left central incisor had a notch-like defect in the incisal edge and had vertical fracture lines labially and palatally, starting from incisal tip extending to the cervical third (Figs 1 and 2). Pulp vitality test showed early response of 11 and all the other teeth responded within normal limits. The tooth showed grade I mobility and was tender on percussion.

On radiographic examination, vertical fracture lines were visible labially and palatally on the middle third, beginning from incisal tip extending to the cervical third in 11 (Fig. 3). Periodontal ligament space widening was seen in relation to the tooth. Based on the dental history, clinical examination, and investigations, it was diagnosed as complicated vertical coronal fracture of 11 with apical periodontitis.

The treatment plan was esthetic management of the fracture followed by endodontic treatment of 11. Horizontal grooves were prepared by tapered fissure diamond abrasive through the fracture line labially and palatally. A long bevel preparation was also done in the fracture line to increase the area of bonding, which binds the

fragments together. After isolation, shade selection was done, etching and bonding was done with self-etch adhesive. Restoration was done with microhybrid resin composite (Tetric N Ceram). Finishing and polishing was completed with polishing disks and strips (Figs 4 and 5).

After esthetic management, root canal treatment was initiated. Shaping and cleaning was done and master cone of size 50 was selected. Obturation was done using lateral compaction technique with controlled pressure to minimize pressure buildup within the root canal. After obturation, gutta-percha was sealed at the cervical level and the access cavity was filled with composite (Fig. 6). Follow-up of the tooth was done at 6, 12, and 18 months. The tooth was asymptomatic and functionally normal. Radiograph showed normal healing. After 18 months metal ceramic crown was done in relation to 11 when the patient attained 17 years of age (Fig. 7).

## DISCUSSION

Management of traumatic injuries has always been a challenge for treatment. Proper diagnosis, treatment, and follow-up care are required to ensure the best possible outcome. The introduction of CBCT helps in diagnosis of root fractures with high accuracy and sensitivity.<sup>10</sup> Factors that might influence the choice of technique include the

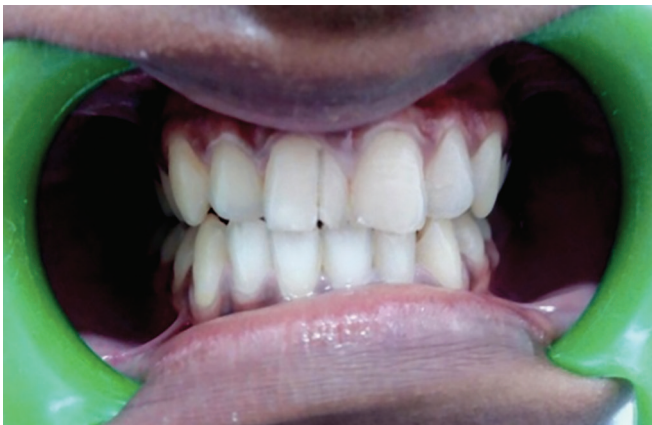

Fig. 1: Preoperative labial view

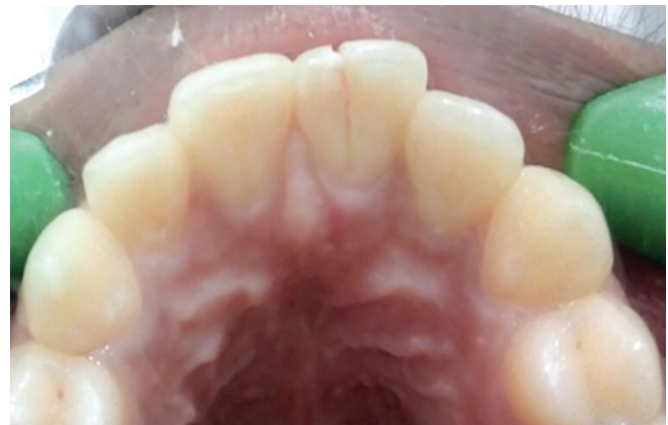

Fig. 2: Preoperative palatal view

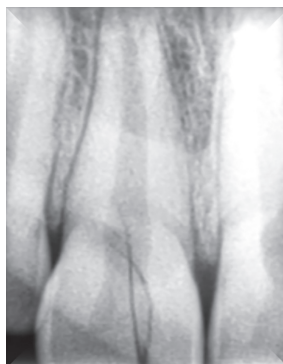

Fig. 3: Preoperative radiograph

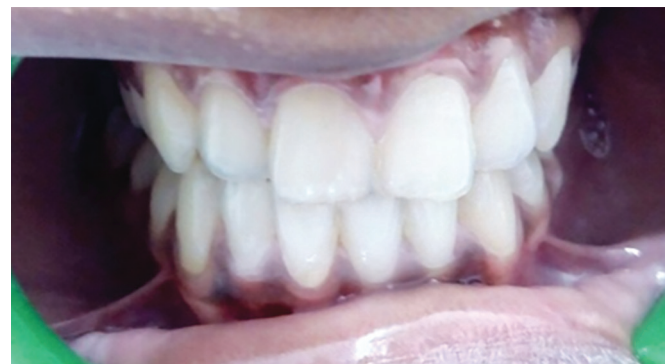

Fig. 4: Postoperative labial view

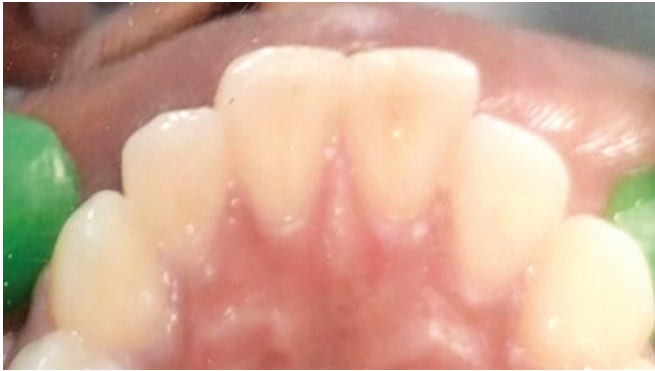

Fig. 5: Postoperative palatal view

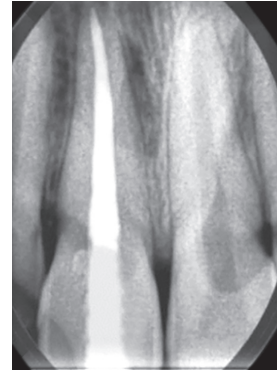


Fig. 6: Postoperative radiograph

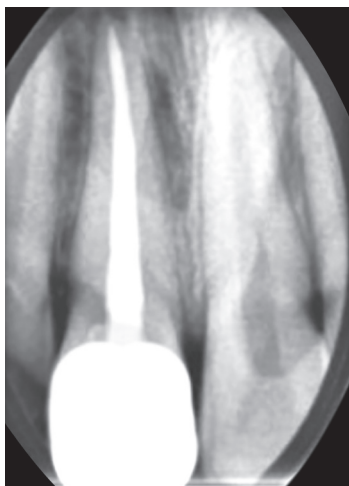

Fig. 7: Follow-up after 18 months

need for endodontic therapy, location, extension of fracture, quality of fit between fragments, and the fracture pattern. In the case presented, the fracture is from the incisal tip to cervical third extending vertically, and the fragments were not separated. Bonding of the fracture was preferred in the initial visit because patient was at a younger age and also it retains the natural esthetics since there is minimal area of intervention.

Various tooth preparation techniques have been described in the literature like circumferential bevel, internal groove, external chamfer, and superficial overcontour of composite on the fracture.<sup>3</sup> Internal groove was given, since this type of preparation showed minimal area of exposure of composite to the surface which gives better esthetics and provides sufficient bulk of composite, which in turn provides strength. The use of an internal groove is preferred when the residual dental structure and the fragment fit perfectly.<sup>4</sup> A long bevel preparation was also done in the fracture line which increases the area of bonding to bind the fragments together. Bevel increased the surface area, leading to greater extension of the restorative material with distributed force around the fracture margin.<sup>11</sup> Restoring the fragments with microhybrid composite in the initial visit was better since it improves

fracture strength and esthetics. Restoring the fracture line and also the coronal seal after the endodontic treatment with composite improves the strength further. Composite resin placed for the restoration of the endodontic access cavity has certainly provided inner reinforcement to the reattached fragment.<sup>12</sup> External reinforcement of the fracture using the metal ceramic crown has been used in the present case.

Remarkable advancement in adhesive system and resin composite has made binding of fragments easier. Thorough knowledge of etiology of fracture, availability of diagnostic methods, and factors determining the prognosis are important to arrive at an appropriate diagnosis and design a suitable treatment protocol.<sup>13</sup> The techniques described in this case report are reasonably simple while restoring function and esthetics with a very conservative approach. The prognosis of the vertical root fracture is poor, so tooth extraction and root amputation are usually the treatment options. The treatment modality presented in this case holds good prognosis since the patient reported immediately after trauma and in the initial visit patient was at a younger age and bonding with composite was preferred since it prevents the extent of fracture line subgingivally. In the present case of vertical coronal fracture, favorable prognosis has been obtained. After 17 years of age, crown was fabricated which further prevented the tooth fragments from separation by occlusal forces to assure functional longevity of the tooth.

## CONCLUSION

Management of vertical coronal fracture for adolescent patient is complex. A proper treatment strategy is needed for the management of tooth with traumatic injuries. Patient cooperation and understanding of the limitations are important for good prognosis. Conservative management of vertical crown fracture is preferred over other treatment options at the initial visit as the patient was at a younger age. Bonding with composite was done

with minimum visit, less expense, and was esthetically acceptable as an emergency treatment. Later, a crown was given as a definitive treatment. However, regular follow-up is essential to assess the treatment outcome.

## REFERENCES

1. Dietschi D, Jacoby T, Dietschi JM, Schatz JP. Treatment of traumatic injuries in the front teeth: restorative aspects in crown fractures. *Pract Periodontics Aesthet Dent* 2000 Oct;12(8):751-758.
2. Maitin N, Maitin SN, Rastogi K, Bhushan R. Fracture tooth fragment reattachment. *BMJ Case Rep* 2013 Jul;2013:009183.
3. Goenka P, Sarawgi A, Dutta S. A conservative approach toward restoration of fractured anterior tooth. *Contemp Clin Den* 2012 Apr;3(Suppl 1):S67-S70.
4. Wiegand A, Rodig T, Attin T. Treatment of crown fractured incisors: reattachment instead of restoration? *Schweiz Monatsschr Zahnmed* 2005 Feb;115(12):1172-1181.
5. Divakar HD, Nayak M, Shetty R. Changing concepts in fracture reattachment of teeth—a case series. *Endodontology* 2007;2:27-35.
6. Worthington RB, Murchinson DF, Vanderwalle KS. Incisor edge reattachment: the effect of preparation utilization and design. *Quintessence Int* 1999 Sep;30(9):637-643.
7. Macedo GV, Diaz PI, Fernandes CA, Ritter AV. Reattachment of anterior teeth fragments: a conservative approach. *J Esthet Restor Dent* 2008 Feb;20(1):5-20.
8. Andreasen FM, Noren JG, Andreasen JO, Engelhardt S, Lindh-Strömberg U. Long term survival of fragment bonding in the treatment of fractured crowns. *Quintessence Int* 1995 Oct;26(10):669-681.
9. Wadhvani CP. Restorative dentistry: a single visit, multidisciplinary approach to the management of traumatic tooth crown fracture. *Br Dent J* 2000 Jun;188:593-598.
10. Chang E, Lam E, Shah P, Azarpazhooh A. Cone-beam computed tomography for detecting vertical root fractures in endodontically treated teeth: a systematic review. *J Endod* 2016 Feb;42(2):177-185.
11. Singla S, Agrawal N, Shashikiran ND. Immediate management of complicated crown fracture: a case series. *SRM J Res Dent Sci* 2015 Aug;6(3):194-197.
12. Kusum B, Heena K, Pandey RK. The management of complicated vertical crown—root fracture in permanent molar: a case report with review of literature. *Int J Oral Health Med Res* 2015 Nov-Dec;2(4):47-51.
13. Altun C, Guven G. Guven combined technique with glass-fibre reinforced composite post and original fragment in restoration of traumatized anterior teeth—a case report. *Dent Traumatol* 2008 Dec;24(6):e76-e80.