

CASE REPORT

Esthetic Management of Complicated Crown Fracture in Anterior Teeth: A Case Report

Mahesh C Mohan¹, Manoj C Kuriakose², Radhakrishnan Nair³, Praveena Geetha⁴, Drisya Soman⁵

ABSTRACT

Coronal fractures of the anterior teeth are a common form of dental trauma that mainly affects children and adolescents. Various treatment modalities have been practiced in the past, but reattachment of fractured fragment is considered to be the most conservative, natural, and esthetic approach. The restoration of natural teeth form, color, and alignment in these patients creates a positive social and emotional response in such patients. This paper reports on conservative management of the fracture of maxillary anterior teeth using two different approaches, namely, one with tooth fragment reattachment and other of recontouring with composite resin.

Keywords: Crown fracture, Dental trauma, Maxillary anterior teeth, Reattachment.

Conservative Dentistry and Endodontic Journal (2019): 10.5005/jp-journals-10048-0051

INTRODUCTION

Traumatic injuries to the teeth and their supporting tissues usually occur in young people and the damage may vary from enamel fracture to avulsion. Most of these injuries occur in anterior teeth especially maxillary incisors.^{1,2} A trauma with accompanying fracture of anterior teeth requires immediate attention, not only because of damage to the dentition but also because of psychologic effect of the trauma. Coronal fractures represent 26–76% of dental injuries in the permanent dentition. The main causes of trauma are falls, collisions, sports violence, and road traffic accidents. If the coronal fracture extends into the subgingival area, the management of fracture is challenging. A number of techniques have been developed to restore the fractured crown, which ranges from simple composite resin restoration to jacket crown. When the tooth fragment is readily available reattachment is a suitable alternative. With the advancement in the field of dental adhesives, reattachment of the fractured segment becomes more predictable treatment. Reattachment of fractured tooth provides the best esthetic results as tooth shape, contour, surface texture, occlusal alignment, and color are maintained.³ Furthermore, this technique is less time-consuming and provides a more predictable long-term wear than when direct composite is used.⁴

Several aspects may govern the choice of a reattachment technique. Studies have reported that the primary cause of fragment loss is a new dental trauma or the nonphysiological use of the restored tooth.⁵ Therefore, most concerns about reattachment techniques have been directed toward the fracture strength of the restored tooth. Clinicians have employed an assortment of bevel designs, chamfers, dentinal and enamel grooves, choices of resin composite materials, and techniques for the reattachment of tooth fragments. In cases of complicated fractures, when endodontic therapy is required, the space provided by the pulp chamber can be used as an inner reinforcement, thus avoiding further preparation of the fractured tooth.^{6,7} If the fractured segment is missing, the replacement of the missing portion can be made using composite restoration, laminates, prosthetic crown placement, etc. Composite restoration is simple, conservative, and less time-consuming among all others. This paper presents the conservative management of

^{1–5}Department of Conservative Dentistry and Endodontics, Azeezia College of Dental Sciences and Research, Kollam, Kerala, India

Corresponding Author: Mahesh C Mohan, Department of Conservative Dentistry and Endodontics, Azeezia College of Dental Sciences and Research, Kollam, Kerala, India, Phone: +91 9961734419, e-mail: drmaheshcm9898@gmail.com

How to cite this article: Mohan MC, Kuriakose MC, Nair R, *et al.* Esthetic Management of Complicated Crown Fracture in Anterior Teeth: A Case Report. *Cons Dent Endod J* 2019;4(2):49–52.

Source of support: Nil

Conflict of interest: None

crown fractures in upper central incisors using two treatment approaches: one with tooth fragment reattachment and the other by restoring missing tooth fragment with composite resin.

CASE DESCRIPTION

A 19-year-old male came to the department with the complaint of fractured and painful upper central incisors. He gave a history of fall a day ago and sought no treatment at that time and reported the next day morning. No relevant medical history was mentioned. Minor soft tissue abrasion was present on the upper lip. Maxillary right and left central incisors were fractured. All other teeth were asymptomatic. In the maxillary right central incisor labially, an oblique fracture was present at the cervical third of the crown which extended subgingivally at the palatal aspect. There was pulp exposure and the fractured segment was mobile. Tooth was tender on percussion and had shown early response to vitality test. The maxillary left central incisor had a fracture at the middle third of the crown involving pulp with the coronal portion of the crown missing. Tooth was tender on percussion and showed early response on vitality test.

The root integrity was evaluated by taking preoperative periapical radiographs. On radiographic examination, tooth 11 showed two oblique lines, corresponding to labial and lingual fracture lines. Periapical area was normal. It was a case of complicated crown fracture with symptomatic irreversible pulpitis.

Tooth 21 showed oblique fracture line at the middle third of the crown and widening of periodontal ligament space was observed. The case was diagnosed as complicated crown fracture of 21 with symptomatic apical periodontitis probably due to the severity of the impact. Endodontic treatment followed by restoration of the crown was the treatment plan.

After giving the local anesthesia for 11, the mobile fractured segment was temporarily splinted to the remaining crown in close approximation using composite resin without acid etching and adhesive application. Endodontic access cavity was prepared through the fractured segment under rubber dam isolation and the root canal obturation was completed using master cone 60 size by cold lateral compaction technique after cleaning and shaping. Post space preparation was done through the fractured segment after gutta-percha removal, retaining about 6 mm at the apical end. The fractured margin at the palatal area was exposed by laser gingivectomy after the removal of fractured fragment. The fragment was again reattached to the sufficiently exposed remaining tooth using dual-cure composite resin after blocking the root canal space using gutta-percha to avoid the flow of composite into the canal. Conditioning of the root canal was done and the fiber post was luted using dual-cure composite after removing the gutta-percha. Incisal one third was missing for 21 and routine endodontic treatment was completed. Root canal obturation was done with gutta-percha by using cold lateral compaction technique. The missing coronal structure was restored with composite resin.

DISCUSSION

Trauma with associated fracture of anterior tooth poses immense distress to a young patient. Reattachment of fractured fragment and preservation of natural tooth form provoke a positive emotional and social response. It is a treatment of choice when there is no or minimal violation of the biological width, with the availability of the dental fragment. Tennery was the first to report the reattachment of a fractured fragment using acid etch technique.⁸ Callavri and Zerman reported that the long-term prognosis for reattachment of crown fragment appears to be better than the composite resin restorations alone. Success of reattachment will depend on how dehydrated the tooth fragment is, because the longer it remains dehydrated, the lesser will be the fracture strength of the tooth.^{9,10} When the case was reported to the department,

the fractured segment in tooth 11 was not separated. During the endodontic procedure and post space preparation, the fragment was kept attached with a temporary splint to reduce the chances of dehydration. This was found to be a favorable factor for the success of reattachment (Figs 1 to 3).¹¹

In the present case, since the biological width was not altered, a periodontal crown lengthening procedure was done using laser gingivectomy for fractured segment reattachment, which ensured sufficient exposure of crown margins for accurate replacement. Resin cement and total etch bonding technique were used for reattachment, considering that the shade, viscosity, and dual-cure mechanism of the cement facilitate the insertion and polymerization. This was a complicated fracture and the pulp space was used for the reinforcement of the fragment. However, in such cases, esthetics may become an important issue as pulpless teeth lose part of their translucency and brightness. Fiber post was placed to reinforce the reattachment segment to improve the retention form and to protect the bond from rotational and twisting forces. Tooth-colored fiber posts have several advantages such as they are more esthetic, bonded to tooth tissue, modulus of elasticity similar to that of dentin, and less chances of fracture. By using glass fiber post with composite core and with recent advances in adhesive techniques and materials, one can create a monobloc, a multilayered structure with no inherent weak interlayer interfaces.¹² An additional use of fiber posts is that it helps to distribute the stress to the remaining radicular dentin. The coronal fragment was missing for 21 and a composite buildup was done to restore the tooth contour. After 18-month follow-up, teeth 11 and 21 were found to be asymptomatic and esthetically acceptable, and no sign of periapical radiolucency was observed (Figs 4 to 9).

CONCLUSION

The management of the trauma depends upon the line of fracture and the amount of the remaining tooth structure. Whenever the fractured segment is available and intact, reattachment is a better approach. For a complicated fracture, root canal treatment is indicated and the pulp space is used for reinforcement. If the fractured segment is missing, the management depends upon the available tooth structure. When there is sufficient coronal structure, composite can be bonded to the crown. Proper instructions should be given after the treatment since even a minor impact can again fracture the crown.

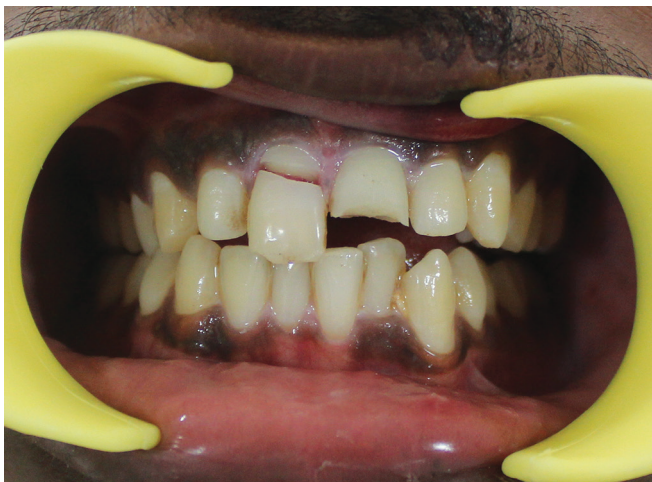

Fig. 1: Preoperative view of teeth 11 and 21—labial aspect

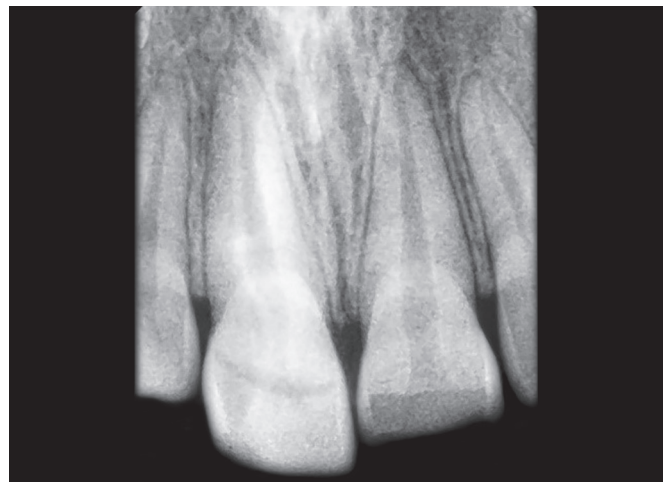

Fig. 2: Preoperative radiographic view

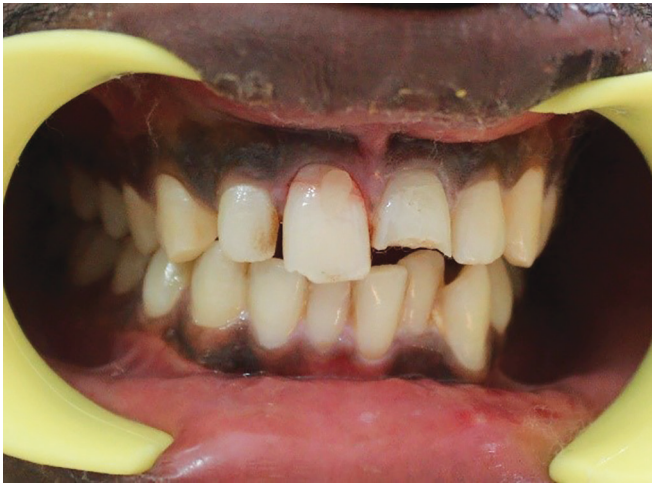

Fig. 3: Composite splinting of fragment

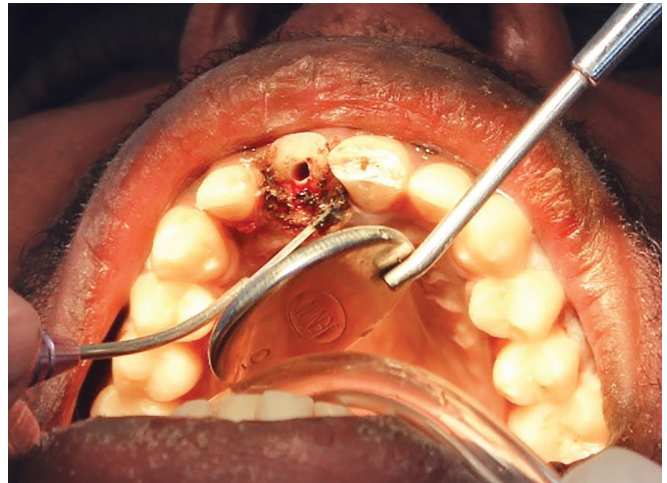


Fig. 4: Laser gingivectomy in palatal aspect of 11

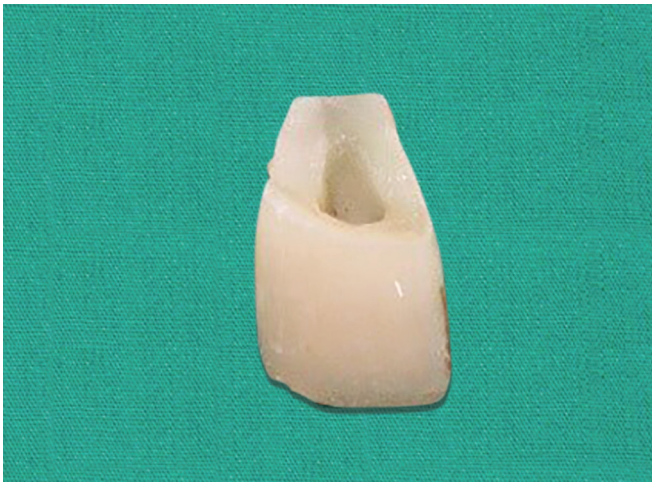

Fig. 5: Fractured fragment

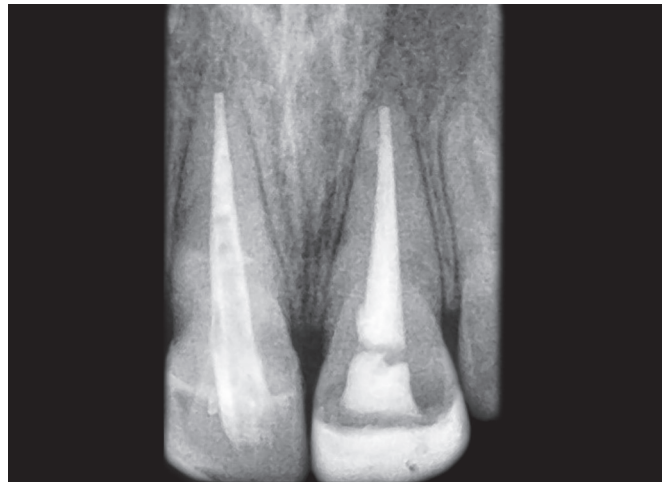

Fig. 6: Postoperative radiograph after fragment reattachment

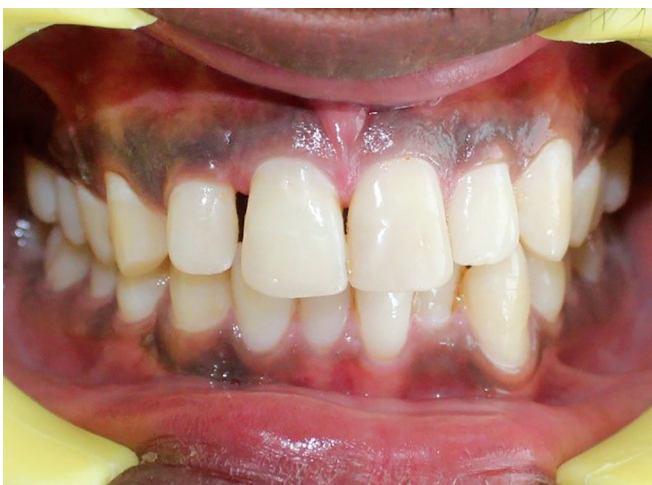

Fig. 7: Postoperative picture after fragment reattachment in 11 and restoration of missing portion with composite in 21

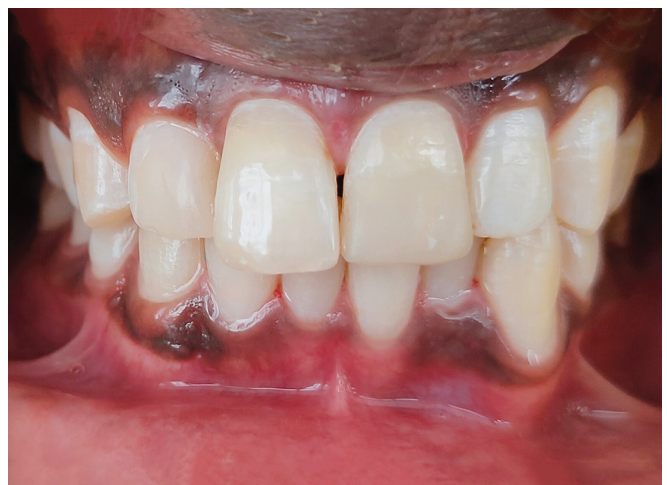

Fig. 8: Review after 18 months

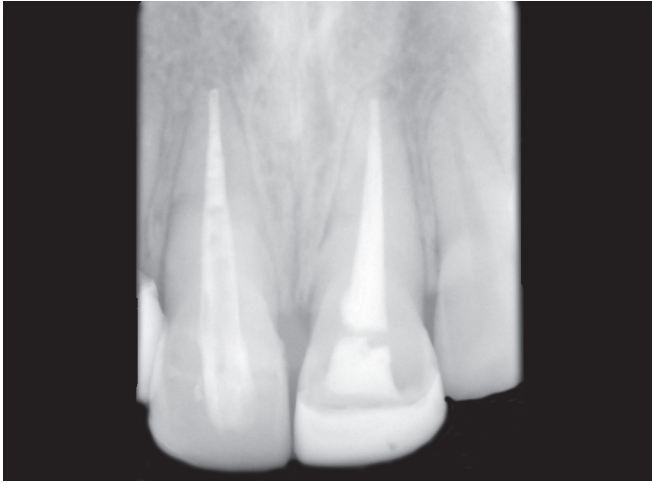


Fig. 9: Review radiograph after 18 months

REFERENCES

1. Andreasen JO, Andreasen F, Andersson L. Textbook and color atlas of traumatic Injuries to the teeth. Classification epidemiology etiology. 4th ed., Oxford: Blackwell; 2007. pp. 227–244.
2. Mojirade AD, Funmilayo A-SIM, Olaida GS. Reattachment of fractured anterior tooth: a 2 year review of a case. *Int J Prosthodont Restor Dent* 2011;1(2):123–127. DOI: 10.5005/jp-journals-10019-1023.
3. Andreasen JO. Tooth and bone loss related to trauma. In: Koch G, Bergendal T, Kvint S. Consensus conference on oral implants in young patients. Stockholm: Forlagshuset Gothia AB; 1996. pp. 40–45.
4. Baratieri LN, Monteiro Jr. S., Andrada MAC. Tooth fracture reattachment: case reports. *Quintessence Int* 1990;21(4):261–270.
5. Andreasen FM, Norén JG, Andreasen JO, et al. Long term survival of fragment bonding in the treatment of fractured crowns. *Quintessence Int* 1995;26(10):669–681.
6. Diangelis AJ, Jungbluth M. Reattaching fractured tooth segments: an esthetic alternative. *J Am Dent Assoc* 1992;123(8):58–63. DOI: 10.14219/jada.archive.1992.0222.
7. Ehrmann EH. Restoration of a fractured incisor with exposed pulp using original tooth fragment: report of case. *J Am Dent Assoc* 1989;118(2):183–185. DOI: 10.14219/jada.archive.1989.0244.
8. Tenner NT. The fractured tooth reunited using the acid etch bonding technique. *Texas Dent J* 1988;96(8):16–17.
9. Shirani F, Malekipour MR, Sakhaei Manesh V, et al. Hydration and dehydration periods of crown fragments prior to reattachment. *Oper Dent* 2012;37(5):501–508. DOI: 10.2341/10-130-L.
10. Rodrigues de Sousa APB, França K, de Lucas Rezende LVM, et al. In vitro tooth reattachment techniques: a systematic review. *Dent Traumatol* 2018;34:297–310.
11. Tay FR, Pashley DH. Monoblocks in root canals: a hypothetical or tangible goal. *J Endod* 2007;33(4):391–398. DOI: 10.1016/j.joen.2006.10.009.
12. Capp CI, Roda MI, Tamaki R, et al. Reattachment of rehydrated dental fragment using two techniques. *Dent Traumatol* 2009;25(1):95–99. DOI: 10.1111/j.1600-9657.2008.00715.x.