

CASE REPORT

Local Drug Delivery as an Adjunct to Surgical Intervention in the Management of Periapical Cyst

¹P Sajith Chandran, ²Anulekh Babu, ³CU Vivekchand, ⁴Lija I Parackal, ⁵Susan Jacob, ⁶Deepthi Simon

ABSTRACT

Radicular cysts are the most common cystic lesions affecting the jaws. They arise from the epithelial remnants in the periodontal ligament as a result of the stimulus from periapical infection following pulpal necrosis. Treatment options to manage large periapical lesions range from nonsurgical root canal treatment or apical surgery to extraction. New approaches involve the use of local drug delivery systems based on microparticles/nanoparticles made from biocompatible polymers along with surgical intervention. Such devices enable the introduction of antimicrobial agents or other drugs directly in the periradicular area or inside the root canal, and the prolonged release of constant concentrations of these agents for fast and better healing. The present case report illustrates the combined endodontic and surgical management of a large periapical cyst with local drug delivery as an adjunct.

Keywords: Biodentin, Hydroxyapatite, Local drug delivery, Periapical cyst.

How to cite this article: Chandran PS, Babu A, Vivekchand CU, Parackal LI, Jacob S, Simon D. Local Drug Delivery as an Adjunct to Surgical Intervention in the Management of Periapical Cyst. *Cons Dent Endod J* 2017;2(1):28-31.

Source of support: Nil

Conflict of interest: None

INTRODUCTION

Periapical cyst is defined as an odontogenic cyst associated with a tooth with a necrotic pulp that develops within a periradicular inflammatory lesion; it derives its epithelium from the cell rests of Malassez. It is the most common odontogenic cyst (52.3–70.7%) and its synonyms include periradicular cyst, apical cyst, apical periodontal cyst, and radicular cyst.¹ A radicular cyst cannot form by itself; therefore, a radicular cyst should

not be considered a separate disease entity from asymptomatic apical periodontitis.

Maxillary anterior teeth are most commonly affected with large periapical lesion due to increased frequency of traumatic injuries in the region.² These kind of lesions can be classified as granulomas, pocket cysts (bay cysts), and true cysts. Granulomas are usually composed of solid soft tissue, while cysts have semisolid or liquefied central area surrounded by epithelium.³

Periapical lesions cannot be definitely diagnosed as either radicular cysts or apical granulomas based on radiographic evidence alone.¹ Two types of cysts have been described in Nair's work, the "true cyst" which presents cavities completely enclosed by epithelial lining, and the "pocket cyst" containing epithelial-lined cavities that present a direct communication to the root canal system. Treatment options to manage large periapical lesions range from nonsurgical root canal treatment and/or apical surgery to extraction. The "true cyst" is considered as conditions with a poor prognosis for nonsurgical endodontics that may only be solved with a surgical approach.⁴

Murphy et al⁵ have reported a high percentage (94.4%) of complete and partial healing of periapical lesions following nonsurgical therapy. When this treatment method is not successful in resolving the periradicular pathosis, surgical intervention can be considered.⁶ New approaches involve the use of local drug delivery systems based on microparticles/nanoparticles made from biocompatible polymers. Such devices enable the introduction of antimicrobial agents or other drugs directly in the periradicular area or inside the root canal, and the prolonged release of constant concentrations of these agents for fast and better healing.⁷

The present case report illustrates the combined endodontic and surgical management of a large periapical cyst with local drug delivery as an adjunct.

CASE REPORT

A 25-year-old male patient reported to the Department of Conservative Dentistry and Endodontics, Government Dental College, Thiruvananthapuram, India, with chief complaint of occasional pus discharge from the labial gingival of upper front teeth. He gave a history of trauma

^{1,4,5}Postgraduate Student, ^{2,6}Associate Professor, ³Senior Resident

¹⁻⁵Department of Conservative Dentistry and Endodontics Government Dental College, Thiruvananthapuram, Kerala, India

⁶Department of Oral and Maxillofacial Surgery, Government Dental College, Thiruvananthapuram, Kerala, India

Corresponding Author: P Sajith Chandran, Postgraduate Student, Department of Conservative Dentistry and Endodontics Government Dental College, Thiruvananthapuram, Kerala, India Phone: +919961035266, e-mail: sajithchandrap@gmail.com

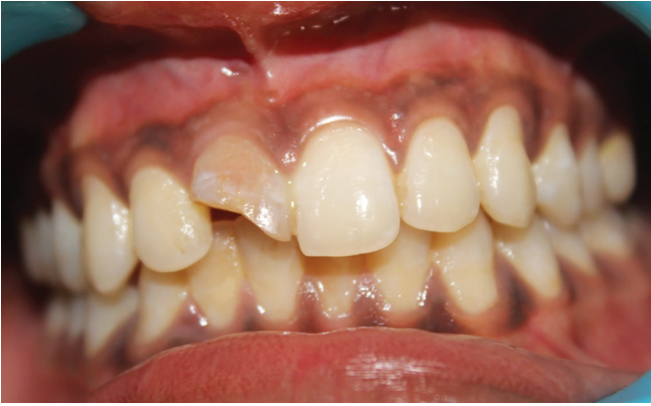

Fig. 1: Preoperative photograph shows Ellis class II fracture and discoloration on 11 and sinus opening

2 years back and had previous history of pain and swelling for which no treatment was sought. Clinically, there was Ellis class II fracture with discoloration on 11 and sinus opening was present (Fig. 1). Vitality was checked, and 11 and 12 showed no response to thermal and electrical pulp testing. Preoperative periapical radiograph revealed a large well-defined periapical radiolucency in relation to 11 and 12. Gutta-percha tracing through sinus revealed the lesion mainly extended around 11 (Fig. 2). Based on the above findings, it was provisionally diagnosed as an infected periapical cyst leaving the definite diagnosis for histopathological analysis.

TREATMENT PLAN

Considering the size of the lesion and the patient's plan to go abroad in the near future, the treatment plan was decided as root canal therapy of 11 and 12 followed by surgical management of the cyst which included cyst enucleation, apicectomy, retrograde filling in relation to 11, and local drug delivery.

Ca(OH)₂ (Dentocal, India) dressing was given in 11 and 12 for 2 weeks. Obturation of 11 and 12 was done with

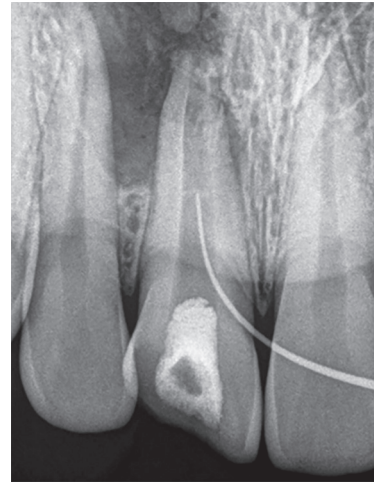


Fig. 2: Preoperative periapical radiograph revealed large well-defined periapical radiolucency in relation to 11 and 12. Gutta-percha tracing through sinus revealed the lesion mainly extended around 11

thermoplasticized gutta-percha on the day of surgery. After administration of local anesthesia, a full thickness mucoperiosteal flap was reflected and irrigated with normal saline. Large buccal bone resorption was present on the site. Complete curettage and enucleation of cyst was done. Then apical 3 mm of the roots was resected for 11, and the retrograde filling was done with biodentin (Septodont, France) (Fig. 3). Bone loss was evident with respect to 11, bone defect was filled with antibiotic-infused hydroxyapatite crystals (Fig. 4). Closure of flap was done with 3-0 silk following hemostasis. The granulation tissue was sent for histopathological examination, and histopathology report confirmed the diagnosis of an infected radicular cyst. On 1 week review, wound was healed (Fig. 5) and full coverage restoration was given after 1 month. At 1-year follow-up, a radiograph was taken in relation to maxillary right central and lateral incisors, which confirmed the satisfactory healing of periapical lesion (Fig. 6).

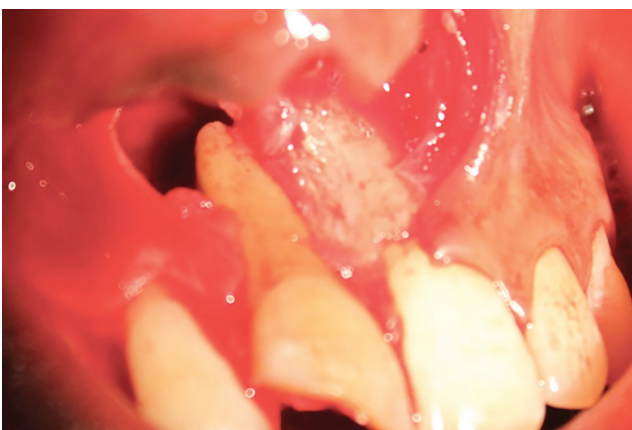

Fig. 3: Cyst was enucleated followed by apicoectomy and retrograde filling was placed with biodentin

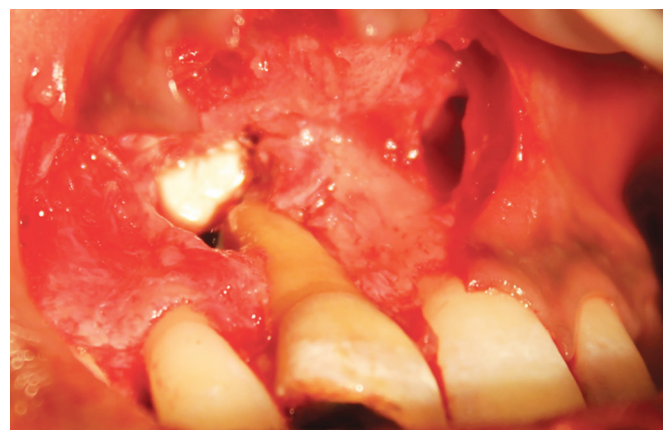

Fig. 4: Bone defect was filled with antibiotic-infused hydroxyapatite crystals

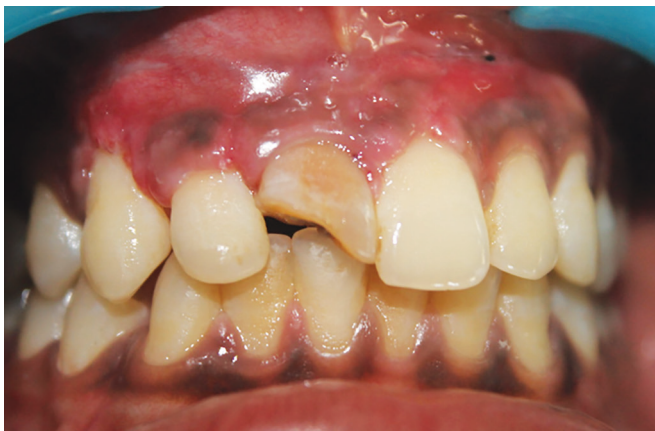

Fig. 5: After 1 week review, the wound was completely healed

DISCUSSION

The exact mechanism of formation of periapical lesions is not fully understood. Necrotic pulp can create suitable environment for the growth of microorganisms and they release various toxins into the periapical tissue initiating an inflammatory reaction and leading to the formation of periapical lesion.^{8,9} Conventional nonsurgical root canal therapy with calcium hydroxide intracanal medication and surgical intervention along with nonsurgical root canal therapy are the two main approaches for the management of periapical lesions. The next option is to go for extraction of particular tooth with curettage of socket followed by prosthetic rehabilitation.²

In this case, $\text{Ca}(\text{OH})_2$ interim medication was given for 1 week, and tooth was obturated on the day of surgery. Calcium hydroxide has the ability to predictably disinfect and neutralize remaining microorganisms in the root canals. Its biological properties are achieved by the dissociation of Ca^{2+} and OH^- ions. The antimicrobial effects of $\text{Ca}(\text{OH})_2$ relate directly to its high pH of 12.5, and it has a destructive effect on cell membranes and protein structures. Since it plays a major role as an interappointment dressing in the disinfection of the root canal system, a $\text{Ca}(\text{OH})_2$ -based paste was used as an antibacterial dressing in this case.¹⁰

Biodentin is used as root-end filling material in the present case. It is a calcium silicate-based material that has drawn attention in recent years and has been recommended for various clinical applications, such as root perforations, apexification, resorptions, retrograde fillings, pulp capping procedures, and dentin replacement. Biodentin holds promise for clinical dental procedures as a biocompatible and easily handled product with short setting time.¹¹

Surgeons have mixed antibiotics, such as tobramycin, gentamicin, cefuroxime, and vancomycin, into bone cement at the time of surgery to provide sufficient

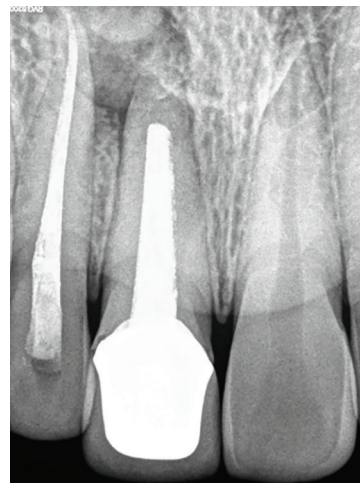


Fig. 6: One-year follow-up radiograph shows the lesion was completely healed

concentrations of antimicrobial agents locally targeting the postsurgical infection.¹² In this case, antibiotic-infused hydroxyapatite crystals are used for filling the bony defect. Here, prepared hydroxyapatite balls were loaded in a syringe, and then ampicillin (Cipla, India) was introduced in the same syringe from ampule. Syringe piston was pushed inward in order to infuse ampicillin into hydroxyapatite balls (one vial ampicillin for five hydroxyapatite balls). Hydroxyapatite crystals (Cadila, India) are used for delivering the drug.⁹ They are well tolerated clinically and do not lead to any allergic reaction.^{13,14} It has bone-conductive properties, which promotes outgrowth of osteogenic cells from existing bone surfaces into the adjacent bone material.^{15,16} Ampicillin is used as a local drug in this case. It is a broad-spectrum antibiotic having a sustained release for 21 days and can prevent infection in surgical wound.

In this case, systemic antibiotic was not used in the entire postoperative period. The benefits of local drug delivery system include high and sustained local concentration, minimized systemic toxicity and adverse reactions, reduced problems with patient compliance, and less chance of development of resistant strains and superimposed infections.¹⁷ A faster healing was evident during the follow-up.

CONCLUSION

The present case highlights the impact of local drug delivery in the management of periapical cyst. Along with the surgical management, incorporation of local drug-delivery system improves better and faster healing of lesion. Apart from that, the local drug delivery system eliminated the use of systemic antibiotic in the post-surgical period and also reduced the need for patient compliance.

REFERENCES

1. Ali M, Baughman RA. Maxillary odontogenic keratocyst: a common and serious clinical misdiagnosis. *J Am Dent Assoc* 2003 Jul;134(7):877-883.
2. Torres-Lagares D, Segura-Egea JJ, Rodríguez-Caballero A, Llamas-Carreras JM, Gutiérrez-Pérez JL. Treatment of a large maxillary cyst with marsupialization, decompression, surgical endodontic therapy and enucleation. *J Can Dent Assoc* 2011;77:b87.
3. Verghese GM, Thomas G, Kuttappa MA, Govind GK. Management of a large periapical cyst (apical matrix & surgical complications) – a case report. *Endodontology* 2009;21(2):84-89.
4. Ramachandran Nair PN, Pajarola G, Schroeder HE. Types and incidence of human periapical lesions obtained with extracted teeth. *Oral Surg Oral Med Oral Pathol Oral Radiol Endod* 1996 Jan;81(1):93-102.
5. Murphy WK, Kaugars GE, Collett WK, Dodds RN. Healing of periapical radiolucencies after nonsurgical endodontic therapy. *Oral Surg Oral Med Oral Pathol* 1991 May;71(5):620-624.
6. Oztan MD. Endodontic treatment of teeth associated with a large periapical lesion. *Int Endod J* 2002 Jan;35(1):73-78.
7. Divya PV, Nandakumar K. Local drug delivery – periocol. *Periodontics* 2006;19(2):74-80.
8. Nair PN. New perspectives on radicular cysts: do they heal? *Int Endod J* 1998 May;31(3):155-160.
9. Dwivedi S, Dwivedi CD, Chaturvedi TP, Baranwal HC. Management of a large radicular cyst: a non-surgical endodontic approach. *Saudi Endod J* 2014 Sep;4(3):145-148.
10. Leonardo MR, Silveira FF, Silva LA, Tanomaru Filho M, Utrilla LS. Calcium hydroxide root canal dressing. Histopathological evaluation of periapical repair at different time periods. *Braz Dent J* 2002;13(1):17-22.
11. Camilleri J. Investigation of biodentine as dentine replacement material. *J Dent* 2013 Jul;41(7):600-610.
12. Henry SL, Galloway KP. Local antibacterial therapy for the management of orthopaedic infections. Pharmacokinetic considerations. *Clin Pharmacokinet* 1995 Jul;29(1):36-45.
13. Maruthmuthu K, Thomas S, Muniapillai S. Efficacy of Chitra granules (porous hydroxyapatite crystals) as an alloplastic bone graft. *JIDAR* 2014 Jan;1(1):15-21.
14. Beck-Coon RJ, Newton CW, Kafrawy AH. An in vivo study of the use of a nonresorbable ceramic hydroxyapatite as an alloplastic graft material in periapical surgery. *Oral Surg Oral Med Oral Pathol* 1991 Apr;71(4):483-488.
15. Shivashankar VY, Johns DA, Vidyath S, Sam G. Combination of platelet rich fibrin, hydroxyapatite and PRF membrane in the management of large inflammatory periapical lesion. *J Conserv Dent* 2013 May;16(3):261-264.
16. Wu P, Grainger DW. Drug/device combinations for local drug therapies and infection prophylaxis. *Biomaterials* 2006 Apr;27(11):2450-2467.
17. Charalambous CP, Tryfonidis M, Swindell R, Lipsett AP. When should old therapies be abandoned? A modern look at old studies on topical ampicillin. *J Infect* 2003 Oct;47(3):203-209.